

Memory encoding in Alzheimer's disease: an fMRI study of explicit and implicit memory

Alexandra Golby,¹ Gerald Silverberg,³ Elizabeth Race,² Susan Gabrieli,² James O'Shea,¹ Kyle Knierim,¹ Glenn Stebbins⁴ and John Gabrieli²

¹Department of Neurosurgery, Brigham and Women's Hospital, Harvard Medical School, Boston, Massachusetts,

²Department of Psychology, Stanford University,

³Department of Neurosurgery, Stanford University Medical Center, Stanford, California and ⁴Department of Neurological Sciences, Rush-Presbyterian-St Luke's Medical Center, Chicago, Illinois, USA

Correspondence to: Alexandra J. Golby, M.D., Department of Neurosurgery, Brigham and Women's Hospital, 75 Francis Street, Boston, MA 02115, USA
E-mail: agolby@bwh.harvard.edu

Summary

Alzheimer's disease is the most common cause of dementia in older adults. Although the cognitive deficits and pathologic hallmarks of Alzheimer's disease have been well characterized, few functional imaging studies have examined the functional competency of specific brain regions and their relationship to specific behavioural memory deficits in Alzheimer's disease. We used functional MRI (fMRI) to examine seven early stage Alzheimer's disease patients and seven healthy age-matched neurologically normal control subjects during intentional encoding of scenes. Subjects viewed blocks of novel scenes, repeated scenes or baseline. Data were analysed using whole-brain statistical parametric mapping and region of interest approaches. The Alzheimer's disease group demonstrated impaired explicit recognition memory, but intact implicit

memory (repetition priming), for the scenes. Alzheimer's disease patients demonstrated a graded deficit in activation for novel versus repeated scenes along the ventral visual stream, with most impaired activation changes in the mesial temporal lobe (MTL) and fusiform regions, most preserved activations in primary visual cortex and variably affected activations in secondary visual areas. Group-level correlations with behavioural measures of explicit memory were found in MTL, lingual and fusiform areas, whereas correlations with priming were found in lateral occipital, parietal and frontal areas. Together, these fMRI findings indicate a dissociation in Alzheimer's disease between impaired explicit memory encoding in MTL and fusiform regions and intact implicit encoding in earlier-stage occipital cortex.

Keywords: Alzheimer's disease; fMRI; memory; encoding; mesial temporal lobe

Abbreviations: AD = Alzheimer's disease; BA = Brodmann area; d' score = discriminability score; fMRI = functional MRI; HRF = haemodynamic response function; L = left; MMSE = Mini-Mental State Examination; NC = normal control; MTL = mesial temporal lobe; R = right; ROI = region of interest; RT = reaction time; SPM = statistical parametric mapping

Received May 4, 2004. Revised December 22, 2004. Accepted December 23, 2004. Advance Access publication February 10, 2005

Introduction

Alzheimer's disease, the most common cause of dementia in older adults, manifests initially with a decline in explicit memory, the conscious recollection of recent experience (Small *et al.*, 1997). Despite consistently impaired explicit (episodic or declarative) memory, Alzheimer's disease patients often exhibit intact implicit (priming or procedural) memory (Fleischman and Gabrieli, 1998). The dissociation between impaired and intact memory capacities presumably

reflects the distinction between neural systems that are injured or spared in the early stages of Alzheimer's disease. Explicit memory deficits in Alzheimer's disease have been linked to pathological, structural and functional abnormalities within the mesial temporal lobe (MTL), based on studies using post-mortem examination (Braak and Braak, 1996), structural imaging (Fox and Schott, 2004), resting metabolism (Herholz, 2003) and functional imaging (Jagust

et al., 1996; Corkin, 1998; Backman *et al.*, 1999, 2000; Small *et al.*, 1999, 2000; Buckner *et al.*, 2000; Saykin *et al.*, 1999; Rombouts *et al.*, 2000; Sperling *et al.*, 2003). These findings are consistent with evidence that MTL structures are essential for the formation of new episodic memories (Scoville and Milner, 1957; Squire and Zola-Morgan, 1991; Squire, 1992).

The brain bases for preserved memory in Alzheimer's disease are less well known, especially for preserved visual priming that is often found in early stage Alzheimer's disease (e.g. Keane *et al.*, 1991). Lesion and functional neuroimaging evidence indicates that higher-order visual areas in the occipital lobe may mediate visual priming (Gabrieli *et al.*, 1995; Keane *et al.*, 1995; Schacter and Buckner, 1998). A functional MRI (fMRI) study of preserved priming in Alzheimer's disease using a semantic classification task demonstrated preserved priming associated with decreases in left inferior frontal cortex activity (Lustig and Buckner, 2004). However, there is no direct evidence as to what brain regions mediate preserved visual priming in Alzheimer's disease.

The goal of the present study was to examine the functional bases of impaired explicit memory and intact implicit memory in Alzheimer's disease as visual information flows hierarchically through the ventral visual stream, from primary through higher order visual cortices and through the MTL. The neuropathologic hallmarks of Alzheimer's disease, neuritic plaques and neurofibrillary tangles, appear first in entorhinal cortex and hippocampus (Braak and Braak, 1996; Simic *et al.*, 1997) and then spread to other MTL and neocortical sites. Some brain regions, including primary sensory and motor cortices, are relatively spared (Arnold *et al.*, 1991). Within modality-specific neocortical areas, the magnitude of pathological changes increases from primary to secondary to tertiary cortices (Lewis *et al.*, 1987). Thus, pathological changes increase in Alzheimer's disease in a hierarchical fashion through the ventral visual pathway.

We hypothesized, therefore, that during visual processing of scenes, Alzheimer's disease patients would show a hierarchical pattern of dysfunction in the ventral visual pathway, with minimal dysfunction in primary and secondary visual cortices and maximal dysfunction occurring in the latest stages of processing in the MTL. Indeed, decreased MTL activation has been observed in Alzheimer's disease during episodic memory encoding (Small *et al.*, 1999; Rombouts *et al.*, 2000; Gron *et al.*, 2002; Sperling *et al.*, 2003). A primary experimental question was whether this difference would be attributable to abnormal perceptual processing (novel stimuli > baseline) or abnormal memory processing (novel > repeated stimuli). Given that the fusiform cortex occupies an intermediate location and stage of processing between primary visual cortex and the MTL, a second question was whether fusiform activation would be relatively preserved, similar to sensory areas, or relatively affected, similar to memory encoding areas. In contrast, because Alzheimer's disease patients have shown intact repetition priming (i.e. facilitation in processing repeated relative

to initial presentations of a stimulus) (Fleischman and Gabrieli, 1998), we predicted that fMRI would demonstrate a dissociation between areas associated with explicit recognition memory and implicit repetition priming. Specifically, it has been proposed that posterior cortical areas that are relatively spared in Alzheimer's disease may support preserved visual repetition priming (Gabrieli *et al.*, 1994).

This study used fMRI activations in response to stimulus novelty as a marker for both explicit and implicit memory encoding. Greater responses for novel than familiar stimuli have been used to identify brain regions important for explicit memory encoding (Stern *et al.*, 1996; Tulving *et al.*, 1996; Gabrieli *et al.*, 1997; Golby *et al.*, 2001*b*) and for implicit memory (Buckner *et al.*, 1995, 1998; Dobbins *et al.*, 2004). In the present study, participants were scanned while they viewed a low-order baseline condition, novel scenes or repeated scenes and judged whether each scene was indoor or outdoor. Both novel and repeated conditions involved the same kind of judgement and the same kind of material; the only difference in these conditions was due to memory for the repeated scenes. Presumably, greater encoding is required for learning novel information than for re-encoding known information. Thus, greater activation for novel than for familiar stimuli is a memory-driven activation that reflects the effectiveness of initial encoding. At the same time, priming, measured by faster or more accurate responses to repeated versus novel stimuli, has been associated with decreased activation in supporting brain regions using a variety of tasks (reviewed in Schacter and Buckner, 1998).

This study is the first to specifically attempt to demonstrate, by fMRI, a dissociation between impaired explicit memory and intact implicit memory in Alzheimer's disease. In addition, specific design features of this study were implemented to: (i) verify that Alzheimer's disease patients were attending to stimuli by measuring their performance during scanning; (ii) include a lower-order condition that allowed for discrimination between perceptual and memory processing; and (iii) measure behavioural performance variables that allowed us to correlate brain activation with measures of clinical severity and of explicit and implicit memory.

Methods

Participants

Seven healthy normal control elderly subjects and seven patients with early Alzheimer's disease [fulfilling National Institute of Neurological and Communicative Diseases and Stroke, Alzheimer's Disease and Related Disorders Association (NINCDS-ADRDA) criteria for probable Alzheimer's disease] participated in the study (Table 1). Participants were excluded if they had concurrent major systemic illness, vasoactive medications or contraindication to MRI scanning. Pre-screening by telephone interview with the patient's carer was used to remove patients who would likely be excluded due to physical limitations, poor cognitive status, concurrent illness, metallic implants or visual impairment. Present or

Table 1 Participant characteristics

	Alzheimer's disease ($n = 7$)	normal control ($n = 7$)
	Mean (SD)	Mean (SD)
Age	69 (8)	66 (11)
Male:female	5:2	4:3
MMSE (maximum = 30)	20.8 (2.0)	29.4 (0.5)
ADAS cog Score	16 (6)	

past use of medication to treat Alzheimer's disease was not an exclusion criterion. Prior to scanning, all participants were fitted with MRI-compatible corrective lenses to correct for refractive errors and their ability to discriminate the visual stimuli was confirmed during pre-scan testing and training. All subjects had the Mini-Mental Status Examination (MMSE) (Folstein *et al.*, 1975) administered by the same examiner (A.G.) before the scanning session. Alzheimer's disease patients scored in the mildly to moderately demented range (18–23, mean 20.8), whereas the normal control participants had no evidence of dementia (29–30, mean 29.4). The two groups did not differ significantly on age [$t(12) = 0.6$, $P > 0.5$]. Each participant gave written informed consent to participate in the study. The Medical Human Subjects Committee at Stanford University approved the study.

Stimuli

Colour photographs of indoor and outdoor scenes were collected from photographic databases (Corel Corporation, Dallas, TX, USA). Photographs were standardized to a common horizontal format. Participants performed two counterbalanced runs of a block-design picture-viewing paradigm with three conditions. The 'novel' condition in each run included 48 non-repeated scenes of which 36 were outdoor and 12 were indoor. The 'repeat' condition contained 48 exposures of the same two repeated scenes, one outdoor (presented 36 times) and one indoor (presented 12 times). The 'baseline' condition was a low-level comparison condition as detailed below.

Stimulus presentation and response collection

Stimuli were presented visually using a magnet-compatible back-projector (Resonance Technology, Inc., Van Nuys, CA, USA). A Macintosh computer with PsyScope software (Carnegie Mellon University, Pittsburgh, PA, USA) generated visual stimuli and controlled experimental parameters. A custom finger switch response system was used to collect responses and reaction times.

Task design

Before entering the scanner room, participants performed a practice run of the behavioural paradigm using the 'repeat' stimuli and practice stimuli until they could perform the task satisfactorily. Participants were asked to respond by button push to outdoor scenes as quickly as possible and were explicitly instructed to try to remember all of the stimuli for a later memory test. After initial localizer and inplane anatomical scans had been obtained, there were two encoding runs. Each run consisted of six cycles of three blocks: (i) novel scenes; (ii) repeated scenes; and (iii) baseline. Stimuli were visible for 2500 ms with a 500 ms interstimulus interval. Novel blocks contained six outdoor and two indoor scenes, each of which was presented only once during the study. Each repeated block contained

the same outdoor scene (repeated six times per block) and indoor scene (repeated two times per block) in a pseudorandom order. Each scene was presented with the prompt 'OUTDOOR?' as a reminder to the participant to push the response button if the photograph was of an outdoor scene. Baseline blocks contained six trials, each consisting of the word 'PUSH' to remind the subject to press the button. This trial type was designed to control both for reading the instruction prompt and button pressing, as well as to remind the participant of the task. If subjects performed the task appropriately, there should have been six button presses per block for all block types.

Following the scanned encoding sessions, an unscanned recognition memory test was administered. Participants were presented with 96 scenes, 48 of which were previously presented during the encoding scan (both the 'novel' and 'repeat' stimuli) and 48 of which were foils, in random order. Each photograph was presented with the prompt 'OLD?' to remind participants of the task. Participants evaluated whether or not each stimulus was previously seen or not and responded with a button press if they remembered seeing the stimuli previously.

Data acquisition

Participants were scanned using a 3T Signa LX Horizon Echospeed MRI system (General Electric, Milwaukee, WI, USA) with a prototype birdcage headcoil. Foam padding around the head was used to minimize movement.

Functional scans

Whole-brain functional imaging was performed using a single-interleave gradient echo spiral pulse sequence (Glover and Lai, 1998), imaging 23 contiguous 6 mm axial slices at 2 s per image volume. The first five subjects were acquired coronally. Inplane spatial resolution was 3.75 mm; TR (repetition time) = 2000 ms; TE (echo time) = 40 ms; 68° flip angle; 24 cm field of view; 64 × 64 matrix acquisition.

Structural scans

T2-weighted spin echo images were acquired for all slices that received functional scans. These were used to verify proper slice selection before functional imaging and to correlate functional activation with anatomical structures. A three-dimensional spoiled gradient-recalled (SPGR) volumetric scan was acquired for Talairach registration and reslicing along different planes.

Behavioural analysis

Responses during the encoding scans were assessed for accuracy (indoor versus outdoor) and reaction times (RT). Implicit memory (repetition priming) for scenes was evaluated by a mixed ANOVA (analysis of variance), between subjects with repeated measures, of RT during scanning. Explicit memory for scenes was evaluated using discriminability (d') scores. Statistical significance was evaluated using a two-tailed t -test.

Imaging analysis

Following image reconstruction, motion correction in three dimensions was performed using the six parameter, rigid-body, least squares realignment routine from SPM99 (Wellcome Department of Cognitive Neurology, London, UK). Average motion was determined using the data output from the motion correction algorithm and calculating the average of the absolute value of translational and

rotational movement in the three cardinal planes. Statistical analysis of movement parameters was performed using an unpaired two-tailed *t*-test. Functional data were spatially smoothed with an 8 mm full width at half maximum (FWHM) Gaussian kernel.

Statistical analysis was performed using SPM99. Analysis was first performed individually for each participant using unnormalized data. Differences between stimulus conditions were examined using the general linear model, modelling stimulus-related activation as a delayed boxcar function convolved with the canonical haemodynamic response function and treating low-frequency signal components as nuisance covariates. Differences in global signal intensity were corrected using proportional scaling to a common mean. The individual (unthresholded) statistical images were then subjected to region of interest (ROI) and statistical parametric mapping (SPM) random effects group analyses (outlined below).

Group analysis was performed on the contrast images derived from the single subject analyses. Normalization was accomplished using SPM99's six parameter least squares rigid-body transformation. The contrast images were normalized into common stereotactic space on the basis of the high resolution volume images, allowing comparison of common regions across multiple subjects. The normalized contrast images were entered into a mixed effects general linear model, treating subjects as a random effect and conditions as a fixed effect and thus allowing population inference. Group analyses were performed for the Alzheimer's disease and normal control groups separately at a threshold of $P < 0.001$, $t = 5.21$ (uncorrected for multiple comparisons) with minimum cluster size > 5 . The Alzheimer's disease group was also displayed at a less stringent threshold of $P < 0.01$, $t = 3.14$ in order to detect any subthreshold activations. Statistical maps were generated for the novel $>$ repeat and were overlaid onto averaged anatomy images created in SPM99 (one was created from all the Alzheimer's disease subjects, one from the normal control subjects and one using all images from both groups). Areas activated by both the normal control and Alzheimer's disease group were calculated using a conjunction analysis across both groups ($P < 0.001$, $t = 5.21$). Areas of differential activation were detected by between group analysis of activation for Alzheimer's disease patients $>$ normal control subjects ($P < 0.001$, $t = 3.93$).

In order to test for correlations between areas of activation and performance measures, three regression analyses were performed using the SPM99 regression routine: activation in the novel-repeat comparison versus recognition memory (d' scores), degree of priming (RT difference for novel and familiar stimuli) and as a measure of clinical disease severity, MMSE scores (for Alzheimer's disease patients only). For all analyses, coordinates of activation were converted from the Montreal Neurological Institute (MNI) coordinates used by SPM to the Talairach coordinates using the mni2tal algorithm (Brett, 1999). Anatomical localization was determined according to the atlas of Talairach and Tournoux (Talairach and Tournoux, 1988) using the computerized Talairach Daemon (Lancaster *et al.*, 1997).

ROIs

Further analysis of ROIs was performed using custom software in Interactive Data Language (Research Systems Incorporated, Boulder, CO, USA). All ROIs were drawn by a single observer extensively trained in neuroanatomy (A.G.). The mesial temporal lobe region was identified visually and outlined bilaterally on each subject's coronal SPGR slices from the amygdala to the atrium of the ventricles. Hippocampal gyrus, parahippocampal gyrus, entorhinal cortex and subiculum were included as described by Amaral and

Insausti (1990). The fusiform gyrus [Brodmann area 37 (BA 37)] was outlined bilaterally on each subject's coronal slices from the aqueduct of Sylvius extending posteriorly for 40 mm. The calcarine cortex was outlined bilaterally on each subject's coronal oblique images perpendicular to the calcarine sulcus. The selected slices started at the occipital pole and extended 20 mm anteriorly (BA 17). Only grey matter was included in the ROIs. Within each of the ROIs, the average response for each contrast was calculated from the values at each voxel within the ROI obtained from the realigned contrast images for that subject. Statistical significance was calculated using a two-tailed unpaired *t*-test.

Results

Behavioural results

Accuracy for the indoor/outdoor judgement during scanning was assessed as percentage correct. The Alzheimer's disease group performed less well (mean of 88.5% correct, SD = 0.17) than the normal control group (mean of 98.0% correct, SD = 0.02). However, both groups performed with high accuracy and did not differ significantly [$t(9) = 1.18$, $P > 0.05$]. Response times for indoor/outdoor judgements were compared with a 3×2 within-subjects ANOVA. Normal control responses were, overall, faster than Alzheimer's disease responses [Alzheimer's disease = 816 ms, normal control = 640 ms; main effect of group, $F(11,1) = 10.0$, $P < 0.05$]. Responses were fastest for the baseline condition (Alzheimer's disease = 662 ms, normal control = 499 ms), slower for the repeated scenes (Alzheimer's disease = 790, normal control = 593) and slowest for the novel scenes (Alzheimer's disease = 993, normal control = 829), demonstrating a main effect of condition [$F(22,2) = 25.9$, $P = 0.0001$] (Fig. 1A). There was, however, no group by condition interaction [$F(22,2) < 1$, $P = 0.87$] demonstrating that the Alzheimer's disease subjects, although slower on all tasks, had the same pattern of responses as the normal control group. A two sample *t*-test of the priming scores for each participant (RT novel – RT repeat) did not show any difference between the groups: mean RT decrease was 236 ms for the normal control subjects versus 204 ms for the Alzheimer's disease subjects [$t(11) = 0.35$, $P > 0.5$]. Explicit or episodic memory, defined by d' on the post-scan recognition memory test, was analysed using a two-tailed *t*-test. Alzheimer's disease subjects had significantly poorer recognition memory for previously seen stimuli than normal control subjects [$t(10) = 2.41$, $P < 0.05$] (Fig. 1B).

Imaging results

Motion parameters did not differ significantly between the two groups. Average translational movement was 0.31 (SD = 0.17) mm for the Alzheimer's disease group and 0.27 mm (SD = 0.12) for the normal control group [$t(10) = 0.42$, $P = 0.68$]. Average rotational movement was minimal in both groups, $< 0.01^\circ$.

Susceptibility artefacts were examined on the subjects' T2* images. There were regions of signal drop-out related to air

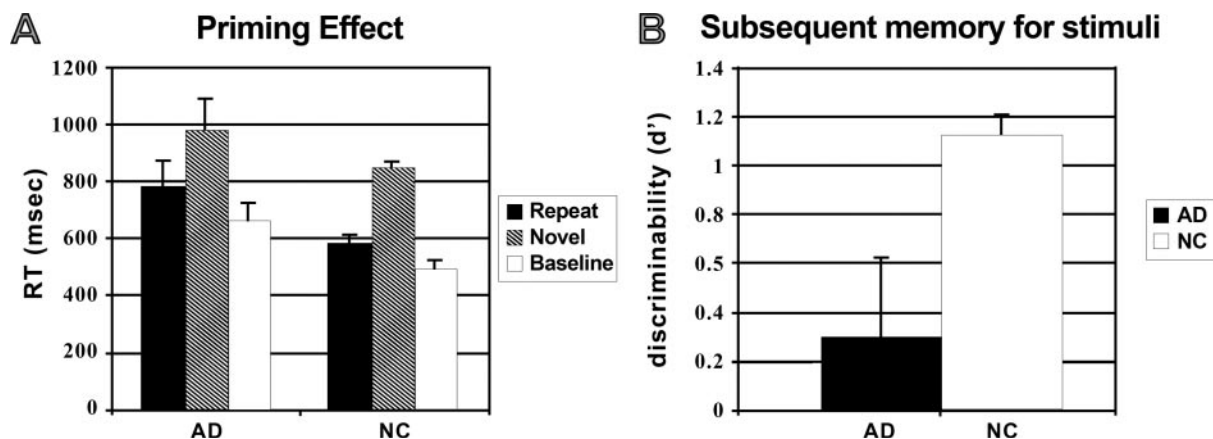


Fig. 1 Behavioural measures. (A) RT for the perceptual task (indoor/outdoor judgement or baseline button push) for the Alzheimer's disease (AD) and NC subjects demonstrate overall slowing of RTs, but preserved priming in the Alzheimer's disease group. (B) d' scores for the Alzheimer's disease and normal control subjects demonstrate that the Alzheimer's disease subjects had significantly poorer recognition memory for the previously presented stimuli than the normal control subjects.

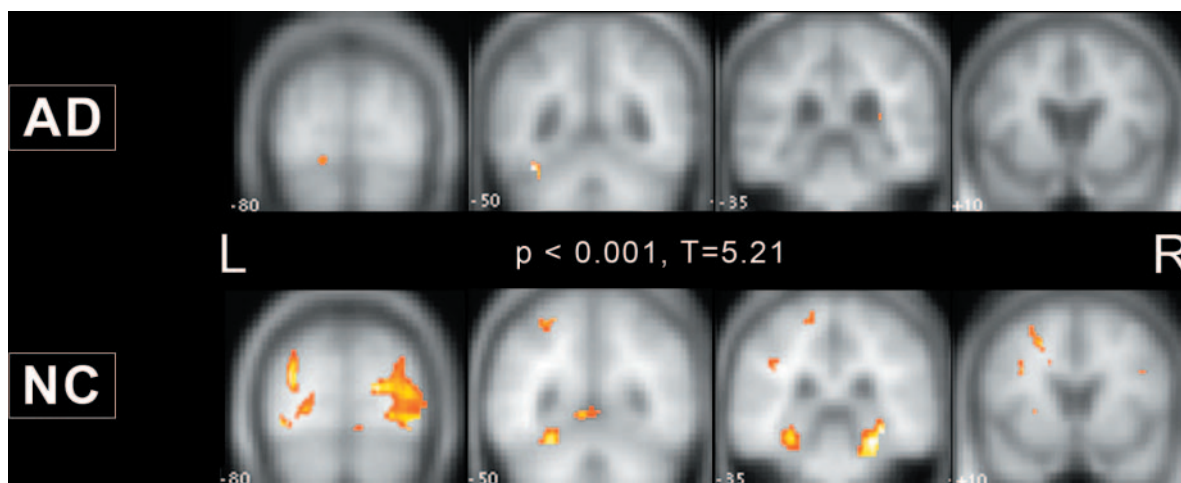


Fig. 2 Group statistical activation maps for the novel > repeat contrast (threshold $P < 0.001$) for the Alzheimer's disease (AD) and normal control (NC) subjects superimposed on averaged anatomical images for each group.

spaces of the sinuses and the mastoid. Drop-out was seen in the most anterior regions of the MTL (amygdala) and in basal frontal regions. Signal loss was not seen within the regions of interest.

The memory encoding comparison (novel > repeat) demonstrated activation for both groups (Fig. 2). The normal control group exhibited reliable activations ($P < 0.001$) in occipital, parietal, temporal and frontal neocortices and bilaterally in the parahippocampal gyri and hippocampus (Table 2). At the $P < 0.001$ threshold, the Alzheimer's disease group had significant clusters of activation in the left fusiform gyrus, lingual gyrus and middle occipital gyrus (Table 3). When the threshold was lowered in the Alzheimer's disease group to $P < 0.01$, these activations had a larger extent resembling those of the normal control group, but there were still no activations in the MTL.

Group level conjunction and difference analyses were performed in SPM to highlight those areas with relative sparing in Alzheimer's disease relative to those areas that were differentially affected. Whereas repetition-associated activation in the medial occipital, left parietal and some fusiform areas were common in the normal control and Alzheimer's disease groups, lateral occipital, other fusiform and MTL activations were greater in the normal control than in the Alzheimer's disease group (Fig. 3 and Table 4). Areas of overlap represent regions that were activated in both groups, but significantly more in the normal control group.

ROI analysis in the MTL, fusiform and calcarine cortices confirmed and extended the findings described above (Fig. 4). Alzheimer's disease subjects had significantly less activation than normal control subjects in the novel > repeat comparison

Table 2 Normal control activations for novel-repeat

Region of activation	L/R	BA	No. of voxels	Talairach coordinates			Z value
				x	y	z	
Precentral/inferior frontal gyri	R	6/9	136	34	-2	28	5.23
Insula/claustrum	L		93	-26	20	3	5.02
Fusiform/lingual/inferior occipital gyri	R	18/19	1875	32	-72	2	4.65
Parahippocampal gyrus/hippocampus	R	35/36/37	457	26	-37	-10	4.28
Middle occipital gyros/cuneus/Middle-temporal gyrus	L	17/18/19	594	-32	-79	19	4.14
Parahippocampal gyrus/fusiform/lingual/hippocampus	L	19/35/36/37	641	-30	-30	-10	4.12
Inferior and middle frontal gyri	L		66	-38	37	0	4.07
Precentral gyrus	R	4/6	45	34	-11	50	4.04
Precuneus	L	7	58	-24	-50	52	3.87
Superior frontal gyrus	L	8	80	-22	12	42	3.85
Frontal lobe white matter	R		23	38	26	15	3.79
Frontal lobe white matter	L		18	-18	51	5	3.75
Frontal lobe white matter	L		50	-34	21	23	3.73
Temporal lobe white matter	L		38	-24	-63	23	3.73
Cuneus/lingual gyrus	R	17/18	69	8	-95	5	3.72
Cingulate gyrus	L	24	40	-8	5	27	3.72
Rostral cerebellum (culmen)	L		66	-6	-49	1	3.71
Inferior parietal lobule	L	40	20	-40	-29	33	3.68
Superior parietal lobule	R	7	21	28	-60	42	3.67
Postcentral gyrus	L	4	18	-16	-32	61	3.66
Cingulate gyrus	L	32	44	-16	19	38	3.60
Precentral gyrus	L	6	49	-32	-11	54	3.57
White matter	L		38	-28	7	16	3.36

$P < 0.001$.

Table 3 Alzheimer's disease activations for novel-repeat

Region of activation	L/R	BA	No. of voxels	Talairach coordinates			Z value
				x	y	z	
Fusiform gyrus	L	37	46	-38	-49	-16	4.33
Lingual gyrus	L	18	42	-24	-70	-7	3.79
Middle occipital gyrus	L	19	3	-30	-91	8	3.33
Lingual gyrus	L	18	8	-12	-88	-16	3.30

$P < 0.001$.

in both the MTL [$t(12) = 3.20$, $P < 0.01$] and fusiform [$t(12) = 2.72$, $P < 0.025$] regions. Activation in the primary visual cortex did not differ significantly between the groups [$t(12) = 1.28$, $P > 0.05$].

Further investigation into the source of these differences between the Alzheimer's disease and normal control group was performed by calculating the activation response to novel and familiar stimuli separately in comparison with the baseline condition (Fig. 4). There was significantly less activation in the Alzheimer's disease group for the novel > baseline contrast in the MTL [$t(12) = 2.13$, $P = 0.05$] and there was a trend for less activation in the fusiform ROI [$t(12) = 2.00$, $P = 0.07$]. There was no significant difference in activation in the calcarine ROI between groups [$t(12) = 1.01$, $P > 0.05$]. In addition, the two groups were similar in the relative magnitude of activation in the three

regions (least in the MTL and greatest in the occipital cortex). While the two groups did not differ significantly in the repeat > baseline contrast, there was a trend in the fusiform gyrus for greater activation for that contrast in the Alzheimer's disease than the normal control group [$t(12) = 1.96$, $P = 0.07$]. There was over twice as much activation in the MTL for the Alzheimer's disease compared with the normal control subjects; however, this difference was not statistically significant [Alzheimer's disease = 9.2, normal control = 4.2; $t(12) = 1.02$, $P > 0.05$]. Thus, the Alzheimer's disease patients tended to have greater activation than the normal control subjects for the repeated relative to the baseline condition, reflecting a failure of the repetition-driven activation reduction seen in the normal control group. Calcarine cortex activation, again, did not differ significantly between the two groups.

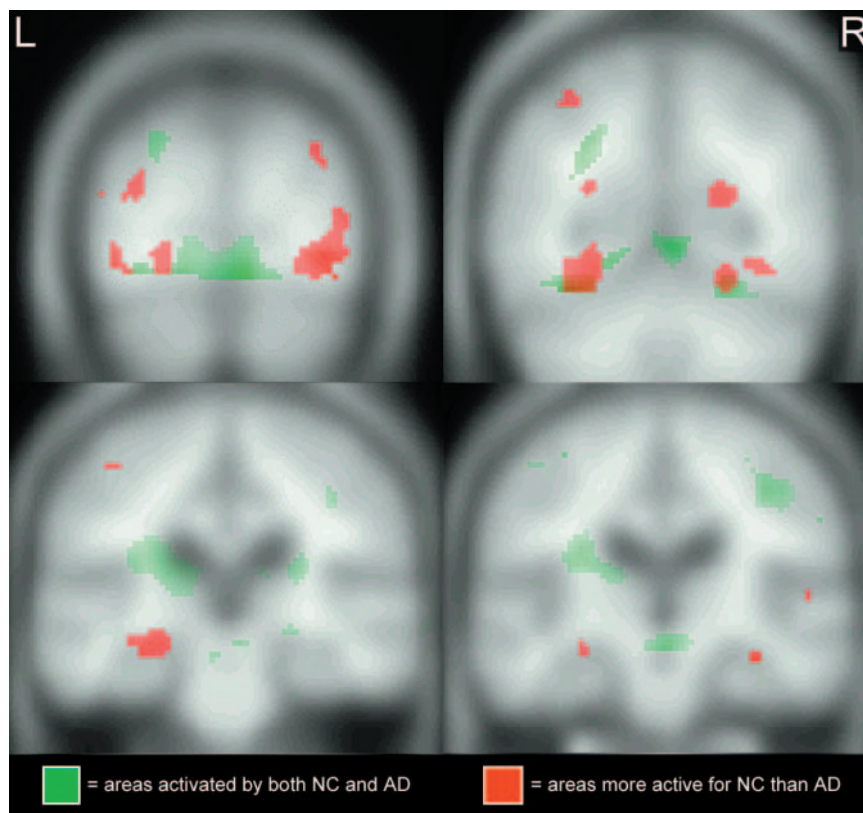


Fig. 3 Group level conjunction and difference analyses ($P < 0.01$) of the novel > repeat contrast demonstrate areas of common activation in both the Alzheimer's disease (AD) and normal control groups (NC) (green) and areas more active in the normal control group than the Alzheimer's disease group (red).

Table 4 Normal control–Alzheimer's disease activations for novel-repeat

Region of activation	L/R	BA	No. of voxels	Talairach coordinates			Z value
				x	y	z	
Fusiform gyrus/parahippocampal gyrus	L	37	102	-28	-41	-11	4.16
Inferior/middle occipital gyrus	R	18/19	121	36	-74	0	3.84
Inferior/middle occipital gyrus	L	19	25	-44	-72	-5	3.76
Lingual gyrus	R	19	42	22	-66	-5	3.54
Fusiform/lingual gyrus	L	19	56	-24	-66	-7	3.53
Rostral cerebellum/PHG	R	36	10	20	-43	-8	3.28
Rostral cerebellum (culmen)	L		6	2	-50	3	3.20

$P < 0.001$.

Correlation with behavioural measures

Three regression analyses were performed in order to examine the relationship of brain activation to explicit and implicit memory performance and clinical disease severity. Using the SPM99 regression routine, regressions were carried out versus d' as a measure of explicit memory, change in RT as a measure of implicit memory, and MMSE scores as a measure of disease severity in the Alzheimer's disease patients. Areas of brain activation that were found to correlate positively with better explicit memory (d') included bilateral lingual gyri (left $r^2 = 0.92$; $P < 0.001$ and right $r^2 = 0.84$; $P < 0.001$), bilateral parahippocampal and fusiform gyrus (left $r^2 = 0.84$; $P < 0.001$ and right $r^2 = 0.81$; $P < 0.001$), paracentral

lobule, inferior and middle occipital gyri and precentral gyrus (Table 5 and Fig. 5A–D). In contrast, areas where the activation correlated positively with priming included left parietal ($r^2 = 0.72$; $P < 0.001$), left cingulate ($r^2 = 0.70$; $P < 0.001$), left middle occipital gyrus (left $r^2 = 0.64$; $P = 0.001$), middle frontal gyrus, pre/post central gyri and rostral cerebellum (culmen) (Table 6 and Fig. 6E–G). Areas that correlated positively with better MMSE scores in the Alzheimer's disease patients were found in the right insular cortex/superior temporal gyrus ($r^2 = 0.94$; $P < 0.001$) and bilateral parahippocampal gyrus and posterior hippocampus (left $r^2 = 0.67$; $P < 0.05$ and right $r^2 = 0.52$; $P = 0.07$) (Table 7 and Fig. 7H–J).

Discussion

This study used fMRI in patients with early stage Alzheimer’s disease and age-matched normal control participants to examine the functional integrity of brain regions associated with

the encoding of explicit and implicit visual memory for scenes. Alzheimer’s disease patients exhibited impaired explicit recognition memory and failed to show the normal activations in response to novel scenes and normal reductions in activation for repeated relative to novel scenes in the MTL and fusiform regions. In addition, activation in these areas was correlated with explicit memory scores. In contrast, Alzheimer’s disease patients had spared behavioural priming and reduced activation for repeated relative to novel scenes in secondary visual areas (BA 18/19), although the extent of these activations was less than in the normal control subjects. Moreover, we demonstrated correlations between activation in parietal, cingulate and secondary visual cortex with the magnitude of repetition priming in both the Alzheimer’s disease and normal control subjects. Thus, using a common testing paradigm, Alzheimer’s disease patients exhibited impaired responses in brain regions associated with explicit memory encoding and intact responses in brain regions that may support visual implicit memory.

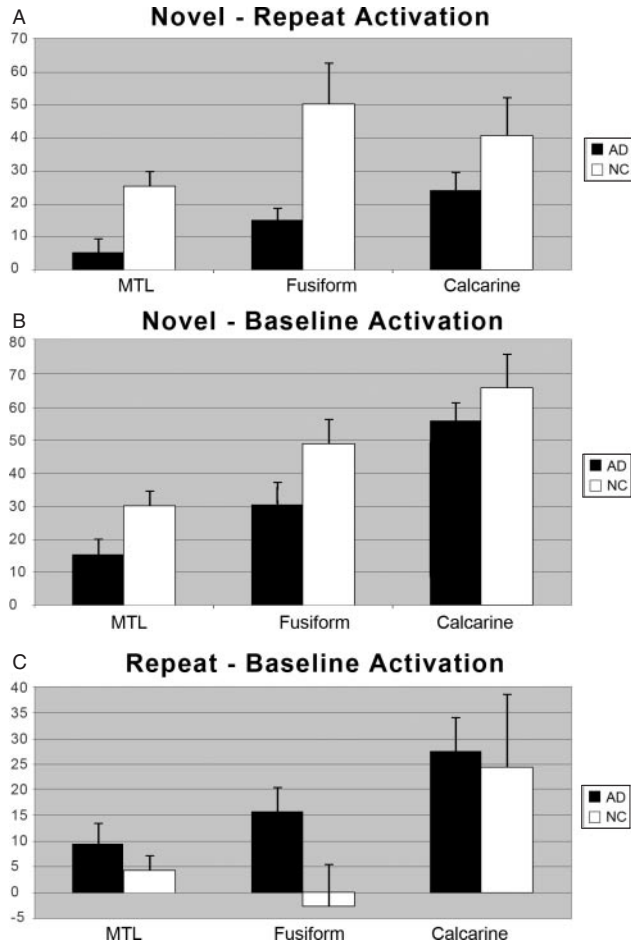


Fig. 4 Mean activation within the anatomical ROIs from the MTL, fusiform and occipital areas for the (A) novel > repeat, (B) novel > baseline and (C) repeat > baseline contrasts. AD = Alzheimer’s disease patients; NC = Normal control subjects.

Explicit memory deficit in Alzheimer’s disease related to dysfunction in anterior fusiform and MTL

Alzheimer’s disease patients had significantly reduced memory activations in the MTL and in frontal, temporal, parietal and cingulate regions. In the ventral visual pathway thought to be critical for encoding visual experience, Alzheimer’s disease patients exhibited a progressive activation deficit from primary through higher order areas. There was no activation deficit in primary visual cortex (calcarine region), but there were significant deficits in higher order fusiform and MTL regions. Moreover, activation in these same higher-order brain areas correlated with explicit memory performance. The clinical significance of the Alzheimer’s disease brain function deficits was demonstrated in an independent analysis showing that the dementia severity (MMSE scores) correlated closely with reduced activations in fusiform and MTL regions. The convergence of these findings implicates

Table 5 Group explicit memory (*d'*) regression activations

Region of activation	L/R	BA	No. of voxels	Talairach coordinates			Z value
				x	y	z	
Lingual gyrus	L	18/19	36	-24	-87	1	4.65
Lingual gyrus	R	18/19	164	18	-64	3	3.95
Fusiform gyrus	L	37	276	-22	-49	-11	3.94
Fusiform gyrus/parahippocampal gyrus	R	37	53	32	-37	-2	3.76
Paracentral lobule/supplementary motor area	R	5	53	2	-43	68	3.72
Inferior/middle occipital gyrus	R	18/19	25	40	-80	1	3.64
Middle frontal gyrus	R	6	17	36	6	48	3.64
Veins/pineal region	R		24	-4	-52	1	3.52
Precentral gyrus	L	4	11	-44	-18	36	3.47

P < 0.001.

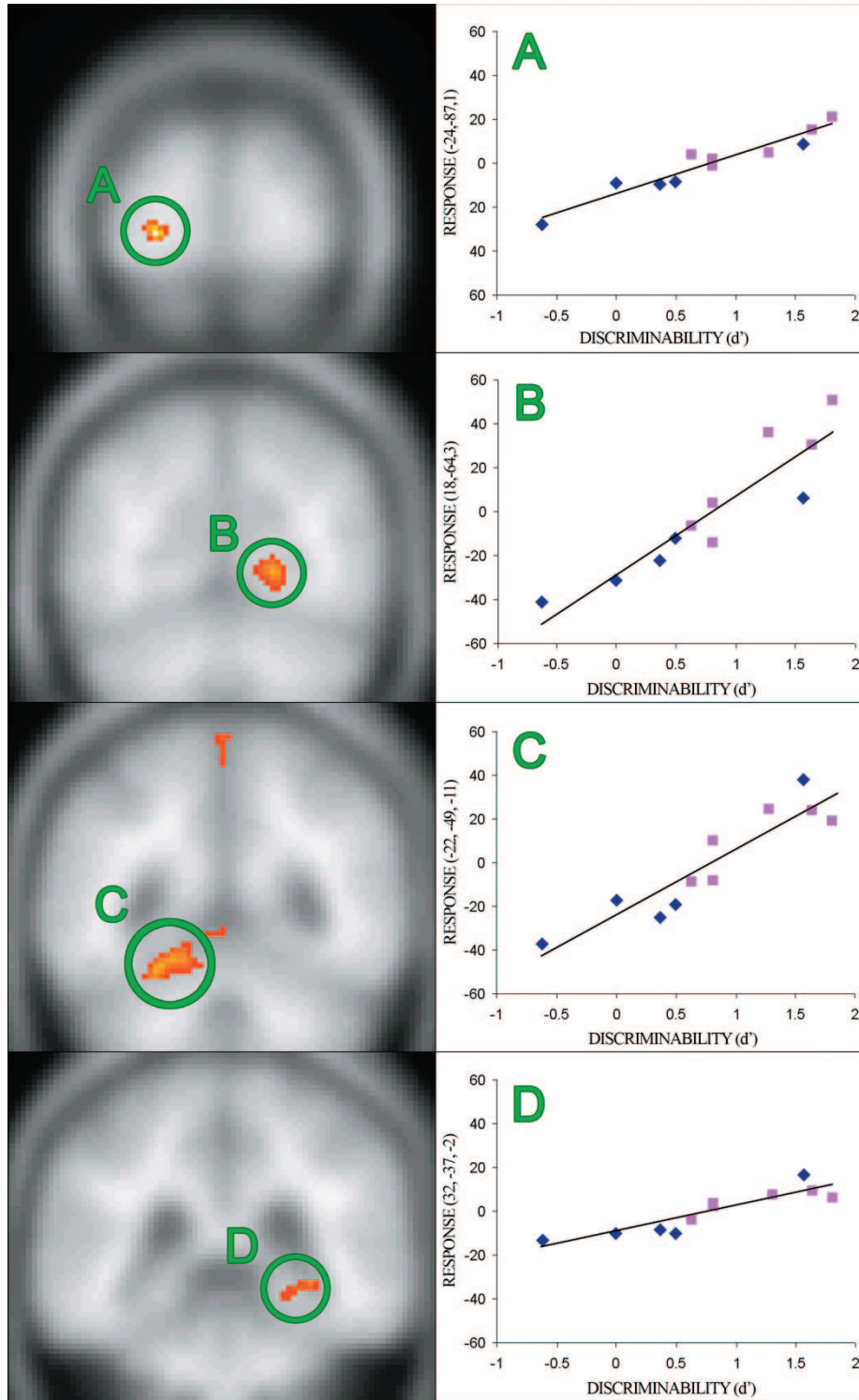


Fig. 5 Regression analysis of correlations of novel > repeat activation with behavioural measures of explicit memory (d') for previously presented stimuli demonstrate brain areas associated with explicit memory processes. Brain areas where activation correlated ($P < 0.001$) with better explicit memory performance include the bilateral lingual gyri (**A** and **B**), bilateral fusiform and parahippocampal gyri (**C** and **D**). \blacklozenge = Alzheimer's disease patients; \blacksquare = normal control subjects.

fusiform and MTL dysfunction in the explicit memory deficit in Alzheimer's disease.

The abnormal MTL memory-associated activation in the Alzheimer's disease subjects is consistent with the declarative

memory deficit in Alzheimer's disease. The critical role of the MTL in memory encoding has been demonstrated in lesion (Scoville and Milner, 1957) and functional imaging studies (Gabrieli *et al.*, 1997; Brewer *et al.*, 1998; Schacter and

Table 6 Group priming (RT change) regression activations

Region of activation	L/R	BA	No. of voxels	Talairach coordinates			Z value
				x	y	z	
Parietal lobe, postcentral gyrus	L		48	-22	-33	48	3.67
Cingulate	L		362	-12	-14	34	3.55
Middle occipital gyrus	L	18,19	163	-28	-75	7	3.28
Cingulate	R	3/4	83	10	-27	46	3.07
Corpus callosum	R		99	6	-10	24	3.06
Superior frontal/precentral gyri	R	6	25	30	-8	63	2.93
Precentral gyrus	L	4	25	-36	-18	34	2.92
Precuneus	L	7	7	-22	-46	43	2.78
Frontal lobe, supplementary motor area	R	6	30	20	-4	43	2.69
Insula	L	13	8	-44	7	-5	2.63
Brainstem	L		15	-6	-16	-1	2.58
Insula	L	13	10	-42	4	3	2.57
Superior temporal gyrus	L		6	-38	-36	15	2.57
Postcentral gyrus	L	3	7	-28	-34	53	2.41

$P < 0.01$.

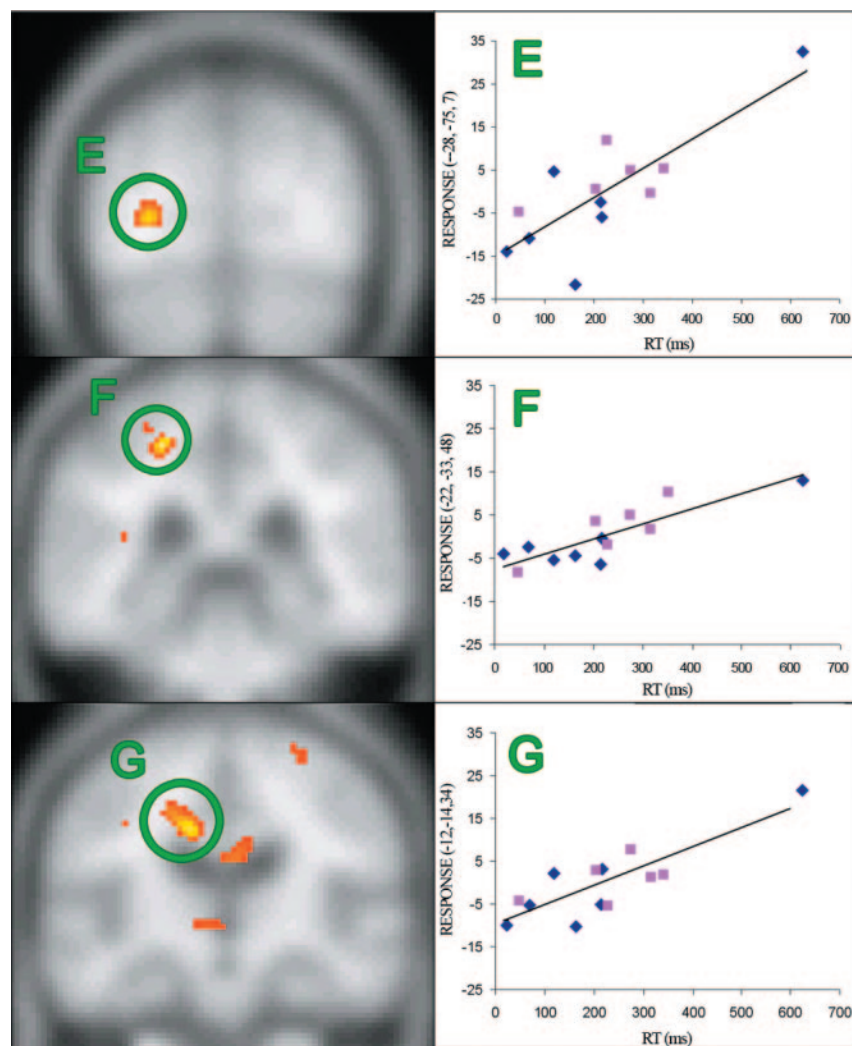


Fig. 6 Regression analysis demonstrates areas correlated with greater priming (RT difference between novel and repeat stimuli). Activation correlations ($P < 0.01$) with greater priming scores were found in the occipital, parietal, and cingulate lobes (E–G). Note differences between these areas where activation correlated with implicit memory performance and areas seen in Fig. 5 where activation correlates with explicit memory performance. ♦ = Alzheimer's disease patients; ■ = Normal control subjects.

Table 7 MMSE: regression in Alzheimer's disease patients

Region of activation	L/R	BA	No. of voxels	Talairach coordinates			Z value
				x	y	z	
Insula/superior temporal gyrus	R		175	36	-25	7	3.58
Basal ganglia/putamen	R		50	28	-10	-5	2.29
Parahippocampal gyrus/hippocampus	L	36/37	67	-22	-45	-6	2.26
Lentiform nucleus/basal ganglia	R		18	24	7	-7	2.15
Superior temporal gyrus	L	12/38	15	-50	-6	-8	2.03
Insula	R		82	36	-12	1	1.97
Parahippocampal gyrus	R	36/37	91	26	-37	-12	1.84
Inferior parietal lobule	R		9	57	-26	25	1.81

$P < 0.05$.

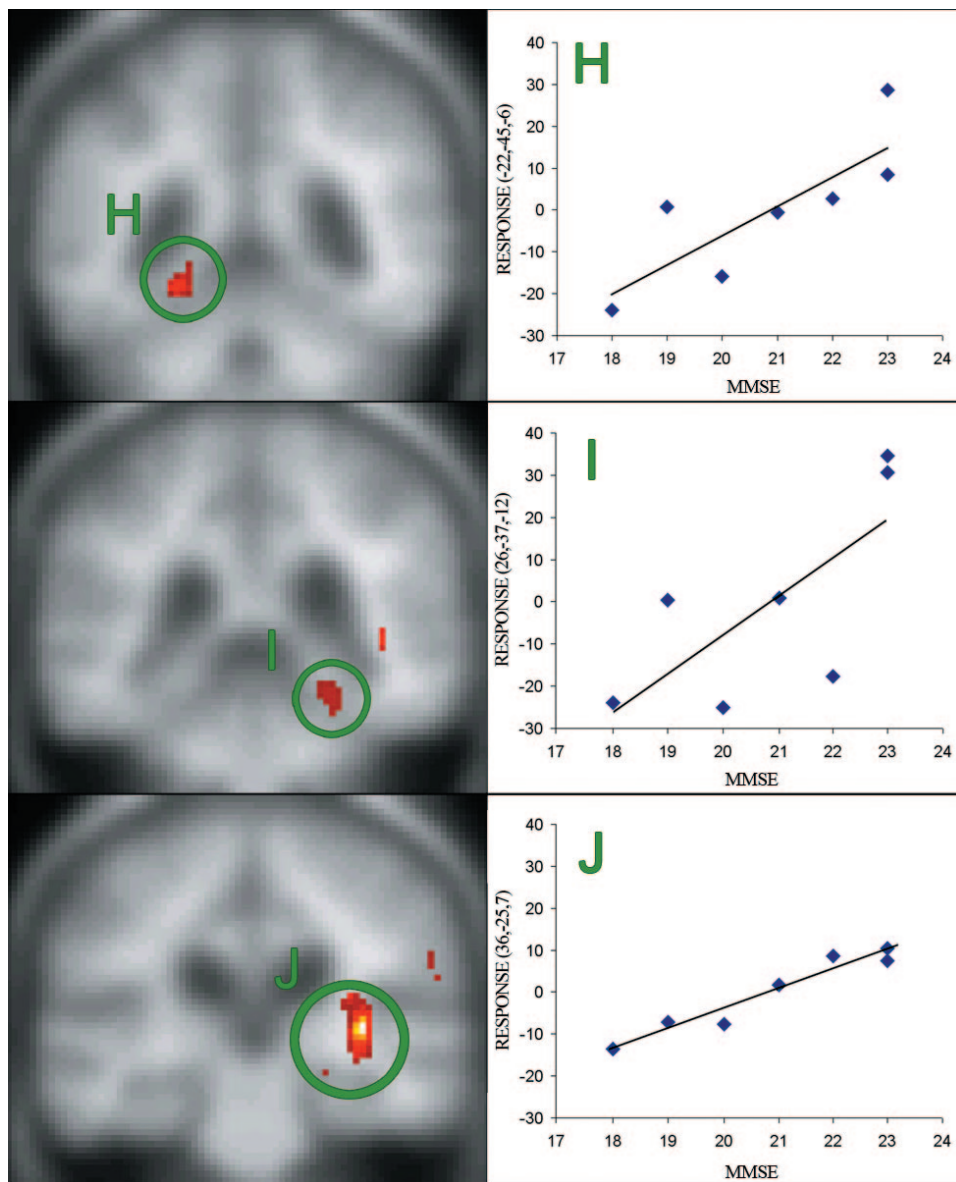


Fig. 7 Regression analysis demonstrates areas in which greater activation in the novel > repeat contrast is correlated with better MMSE scores in the Alzheimer's disease subjects. Activation in the left fusiform gyrus (**H**) and bilateral parahippocampal gyri and posterior hippocampus (**I** and **J**) correlated with better performance on the MMSE ($P < 0.05$).

Wagner, 1999). Other imaging studies demonstrate that in healthy subjects and patients repeated exposure to the same stimuli is associated with decreased activation of multiple cortical areas and in particular of the MTL (Tulving *et al.*, 1996; Dolan and Fletcher, 1997; Gabrieli *et al.*, 1997; Martin, 1999; Golby *et al.*, 2001b, 2002). Moreover, the areas that show reduction in activation with repetition are the same areas in which the magnitude of response for a once-seen stimulus predicts subsequent memory (Kirchhoff *et al.*, 2000). Although not traditionally thought of as memory supporting, there is also evidence that the fusiform cortex may be involved in memory, particularly for visually presented materials (Damasio *et al.*, 1996; Mesulam, 1998; Kirchhoff *et al.*, 2000; Golby *et al.*, 2001a).

Several functional imaging studies have examined explicit memory encoding in Alzheimer's disease. In a PET study, Backman *et al.* (1999) used a word-stem cued recall paradigm in Alzheimer's disease and healthy elderly participants. They found that Alzheimer's disease patients had impaired explicit memory and reduced activation in hippocampus and temporo-parietal regions relative to healthy elderly when completing word stems of previously seen words compared with new word stems. Sperling *et al.* (2003) used a face-name association encoding paradigm with novel, familiar and fixation conditions in an fMRI experiment of young and older healthy subjects and Alzheimer's disease patients. As in our study, they found decreased novelty-associated activation in the hippocampus for the Alzheimer's disease subjects compared with the older controls. However, whereas we found both decrease in the novel condition relative to baseline and increase in the repeat condition relative to baseline, they found decreased hippocampal activation for the repeat-fixation comparison in the Alzheimer's disease patients. The same study also found Alzheimer's disease patients had greater fusiform activation than older control subjects in novel-repeat comparison—again differing from our findings. It is possible that differences in the task paradigm and analysis protocols account for these differences. Our findings of graded disruption by Alzheimer's disease along the ventral visual stream would suggest that the more posterior fusiform areas adjacent to visual areas are less likely to be affected than more anterior areas. In a related study, the same group examined the effects of pharmacological interference with encoding (Sperling *et al.*, 2002). That study found significant decreases in hippocampal and fusiform activations during encoding with the administration of lorazepam or scopolamine compared with encoding without pharmacological interference. Analogous to our findings, they did not find a decrease in striate cortex activation during drug administration. Another study investigating Alzheimer's disease patients during repetitive learning and free recall of abstract patterns also found decreased activation in bilateral hippocampi compared with healthy subjects (Gron *et al.*, 2002). Together, these results suggest that the fusiform and hippocampal regions are involved in encoding complex visual material and that disturbance of encoding associated either

with disease or with pharmacological disruption is accompanied by abnormal novelty-associated activation in these regions.

Thus, Alzheimer's disease patients in both previous and present studies failed to exhibit memory-driven alterations of MTL activation for novel relative to familiar stimuli. An unexpected finding was that the decreased response seen in the Alzheimer's disease patients for the novel-repeat comparison was due to both a decrease (but not absence) of response in the novel-baseline comparison and an increase in the repeat-baseline comparison. This finding argues against simply atrophy or haemodynamic changes underlying the absence of a memory-induced MTL activation in Alzheimer's disease. The partially spared MTL response is somewhat surprising given the MTL atrophy seen on post-mortem neuropathological examination (Braak and Braak, 1996; Simic *et al.*, 1997) and the decreased MTL signal on studies of resting metabolism (Tohgi *et al.*, 1998; Yamaguchi *et al.*, 1997). Nevertheless, the partially preserved MTL response to the novel scenes versus baseline makes the absence of a memory-induced reduction in activation for repeated scenes versus baseline in the Alzheimer's disease patients all the more striking. The present results suggest that MTL function is not absent in Alzheimer's disease, but rather shows a graded deficit that correlates with clinical measures and behavioural performance. In the present study, we found correlations between MMSE scores and MTL activation in the Alzheimer's disease patients. Similarly, Eustache *et al.* (2004) in a recent PET study of Alzheimer's disease patients found a correlation between right hippocampal activation and autobiographical memory scores. Interestingly, an fMRI study in patients with mild cognitive impairment demonstrated that increased MTL activation was associated with worse clinical status and was predictive of subsequent cognitive decline (Dickerson *et al.*, 2004). Together these findings suggest that, in early Alzheimer's disease, there may not be wholesale disruption of MTL function and that future therapeutic interventions may be aimed at maximizing residual function.

Intact implicit memory in Alzheimer's disease related to spared function in occipital cortex

Results from the present study suggest that early stage Alzheimer's disease spares functions of secondary visual cortices and attentional areas that may support the visual implicit memory that was intact in the Alzheimer's disease patients. The magnitude of activation in the left middle occipital gyrus extrastriate visual region (BA 18/19) for novel > repeat scenes correlated with the magnitude of behavioural priming (as did activations in parietal and cingulate regions). The Alzheimer's disease patients also showed a spared activation for novel relative to familiar scenes in the left middle occipital gyrus. These results suggest that areas involved in relatively earlier stages of visual processing and response selection retain their integrity and may support preserved implicit memory capacity in Alzheimer's disease. An

fMRI study with healthy subjects found evidence that some forms of repetition priming are mediated by procedural learning of stimulus-response mappings (Dobbins *et al.*, 2004) and, perhaps, the activations reflect the response aspect of such a mapping. These findings are consistent with previous behavioural findings of intact visual repetition priming in Alzheimer's disease. The present study suggests that such priming may reflect spared function in secondary visual, parietal and cingulate cortices.

Many functional imaging studies have investigated visual priming in healthy populations using a large variety of tasks. Buckner *et al.* (1998) found that perceptual priming-associated reductions in activation took place not in early stage retinotopic cortex, but rather in higher level visual areas. In our previous study employing a novelty paradigm to study the lateralization of encoding processes (Golby *et al.*, 2001b), we found familiarity-induced activation reductions in lateral occipital areas when healthy participants viewed these same scene stimuli. These and other studies of perceptual priming (Blaxton *et al.*, 1996) suggest that the preserved activation reductions for repeated stimuli in secondary visual cortex seen in the Alzheimer's disease patients in the present study could underlie the preserved behavioural priming.

There are several functional neuroimaging studies of repetition priming in Alzheimer's disease. Backman *et al.* (2000) used word-stem completion priming—a form of repetition priming that is usually impaired in Alzheimer's disease—in their PET study of implicit memory. Alzheimer's disease patients exhibited impaired priming and altered priming-associated responses in extrastriate visual cortex. In contrast, a more recent study found that spared repetition priming in a conceptual word priming task was associated with spared responses in the inferior frontal cortex of Alzheimer's disease patients (Lustig and Buckner, 2004). Both the perceptual judgements in the present study and the conceptual judgements in the study by Lustig and Buckner (2004) involve identification tasks which often yield intact priming in Alzheimer's disease for both perceptual and conceptual tasks (Gabrieli *et al.*, 1999). In contrast, production tasks, such as word stem completion, often yield impaired priming in Alzheimer's disease (e.g. Backman *et al.*, 2000), perhaps due to the greater attentional demands for production priming (Gabrieli *et al.*, 1999). These task differences make direct comparisons between the small number of studies using functional imaging to investigate priming in Alzheimer's disease difficult. In addition, susceptibility artefact in the basal frontal regions resulted in decreased sensitivity of our study to detect activation changes in the inferior frontal gyrus as seen in the word repetition priming study by Lustig and Buckner (2004). Advances in scanning sequences that minimize such susceptibility have been made since our data were collected and future studies with such sequences may better reveal potential inferior frontal contributions to visual priming in Alzheimer's disease.

There remain many questions about the neural correlates of specific types of priming that are preserved or impaired

in Alzheimer's disease. By directly comparing explicit and implicit memory-associated measures, however, our functional imaging findings are the first to directly dissociate impaired and intact neural memory systems in Alzheimer's disease. Our results are consistent with a prior study which found a dissociation between activations associated with explicit retrieval and those associated with implicit priming in healthy young people (Donaldson *et al.*, 2001).

Several factors may influence fMRI findings in Alzheimer's disease

Behavioural and biological factors that may complicate the interpretation of fMRI findings in Alzheimer's disease must be considered. In order to draw valid conclusions, functional imaging studies depend on proper performance of the task by the subjects. This study used several features to ensure and measure adequate task performance. Task instructions were simple and re-presented during the test, and subjects practised the task until they could perform it adequately. The Alzheimer's disease patients performed well on the perceptual task. This indicates that patients were attending to and understanding the scenes and that activation differences cannot be accounted for by simple attention or performance differences.

Brain alterations in Alzheimer's disease may also complicate interpretation. Brain atrophy in Alzheimer's disease patients is likely to be related to both psychological and neural processes and, in turn, to the signal measured by fMRI. This study used both a whole brain analysis and an individually drawn ROI analysis taking into account the variability in grey matter volume. The convergent results from normalized whole-brain and individually drawn ROI analyses suggest that artefactual alterations introduced by focal brain atrophy were not driving our findings. It is also possible that the Alzheimer's disease process may be associated with changes in the haemodynamic response function (HRF) to neuronal activity. Because fMRI measures changes in blood flow as a proxy for neuronal activation, HRF changes could influence the result separately from neural processing. D'Esposito *et al.* (1999) suggest that there may be decreased ability to detect activation in elderly subjects if the HRF is disturbed. Two kinds of evidence suggest that alterations in the HRF are unlikely to be the major source of group differences in the present study. First, although regional differences in the magnitude of the HRF between young, older and demented subjects have been demonstrated, the summation of the haemodynamic response are highly similar across brain regions between groups suggesting that relative activation change should be preserved (Buckner *et al.*, 2000). Secondly, there were multiple examples, in the present study, of preserved fMRI activations in the Alzheimer's disease patients, including activations in primary visual areas and activation to repeat scenes versus baseline in the MTL, which argue against a generalized alteration of the HRF in Alzheimer's disease in this study.

Conclusion

In summary, the Alzheimer's disease patients in this study demonstrated three patterns of activation that may be fundamentally characteristic of early stage Alzheimer's disease. First, they exhibited intact activation in the early stage ventral visual pathway in response to complex visual scenes relative to baseline. This intact activation is consistent with spared basic perception in early Alzheimer's disease. Secondly, Alzheimer's disease patients exhibited normal implicit memory for the scenes as measured behaviourally by intact repetition priming and, as measured via fMRI, by priming-correlated reductions of activation in secondary visual processing areas, which may support visual perceptual priming. Thirdly, Alzheimer's disease patients exhibited a progressive impairment of memory-induced alterations in activation, with an absence of experience-modulated activation in fusiform and MTL regions. This finding is consistent with the idea that Alzheimer's disease impairs functioning of the ventral visual stream in a hierarchical fashion, with the least compromise in earlier visual areas and the greatest compromise in later stages of visual processing and declarative memory, namely fusiform and MTL regions. Indeed, the absence of a memory-induced alteration in MTL activation in Alzheimer's disease patients is a sort of brain activation amnesia that parallels their behavioural amnesia in that prior experiences fail to leave a mark on consciously available memories (i.e. MTL responses to novel and highly familiar scenes were similar in Alzheimer's disease patients). On the other hand, some areas, specifically those supporting certain priming processes, appear to be relatively spared in early Alzheimer's disease. Even in affected areas such as the MTL, some perceptual responses to novel stimuli may still be elicited. This finding is particularly intriguing as it suggests that, in early Alzheimer's disease, much of the circuitry within these regions may still be functional and may therefore open the door for pharmacological or other therapies. Functional imaging, in concert with other investigative methods will be important in understanding the pathophysiology and natural history of Alzheimer's disease and may provide a tool to evaluate interventions targeted at slowing or reversing the course of the disease.

References

- Amaral D, Insausti R. Hippocampal formation. In: Paxinos G, editor. The human nervous system. San Diego: Academic Press; 1990. p. 711–55.
- Arnold SE, Hyman BT, Flory J, Damasio AR, Van Hoesen GW. The topographical and neuroanatomical distribution of neurofibrillary tangles and neuritic plaques in the cerebral cortex of patients with Alzheimer's disease. *Cereb Cortex* 1991; 1: 103–16.
- Backman L, Andersson JL, Nyberg L, Winblad B, Nordberg A, Almkvist O. Brain regions associated with episodic retrieval in normal aging and Alzheimer's disease. *Neurology* 1999; 52: 1861–70.
- Backman L, Almkvist O, Nyberg L, Andersson J. Functional changes in brain activity during priming in Alzheimer's disease. *J Cogn Neurosci* 2000; 12: 134–41.
- Blaxton TA, Bookheimer SY, Zeffiro TA, Figlozzi CM, Gaillard WD, Theodore WH. Functional mapping of human memory using PET: comparisons of conceptual and perceptual tasks. *Can J Exp Psychol* 1996; 50: 42–56.
- Braak H, Braak E. Evolution of the neuropathology of Alzheimer's disease. *Acta Neurol Scand Suppl* 1996; 165: 3–12.
- Brett M. The MNI brain and the Talairach atlas: mni2tal. MRC Cognition and Brain Sciences Unit, Cambridge, 1999. <http://www.mrc-cbu.cam.ac.uk/Imaging/Common/mnispace.shtml>
- Brewer JB, Zhao Z, Desmond JE, Glover GH, Gabrieli JDE. Making memories: brain activity that predicts how well visual experience will be remembered. *Science* 1998; 281: 1185–7.
- Buckner RL, Petersen SE, Ojemann JG, Miezin FM, Squire LR, Raichle ME. Functional anatomical studies of explicit and implicit memory retrieval tasks. *J Neurosci* 1995; 15: 12–29.
- Buckner RL, Goodman J, Burock M, Rotte M, Koutstaal W, Schacter D, et al. Functional-anatomic correlates of object priming in humans revealed by rapid presentation event-related fMRI. *Neuron* 1998; 20: 285–96.
- Buckner RL, Snyder AZ, Sanders AL, Raichle ME, Morris JC. Functional brain imaging of young, nondemented and demented older adults. *J Cogn Neurosci* 2000; 12: 24–34.
- Corkin S. Functional MRI for studying episodic memory in aging and Alzheimer's disease. *Geriatrics* 1998; 53 Suppl 1: S13–5.
- Damasio H, Grabowski TJ, Tranel D, Hichwa RD, Damasio AR. A neural basis for lexical retrieval. *Nature* 1996; 380: 499–505.
- D'Esposito M, Zarahn E, Aguirre GK, Rypma B. The effect of normal aging on the coupling of neural activity to the bold hemodynamic response. *Neuroimage* 1999; 10: 6–14.
- Dickerson B, Salat D, Bates J, Atiya M, Killany R, Greve D, et al. Medial temporal lobe function and structure in mild cognitive impairment. *Ann Neurol* 2004; 56: 27–35.
- Dobbins IG, Schnyer DM, Verfaellie M, Schacter DL. Cortical activity reductions during repetition priming can result from rapid response learning. *Nature* 2004; 428: 316–9.
- Dolan RJ, Fletcher PC. Dissociating prefrontal and hippocampal function in episodic memory encoding. *Nature* 1997; 388: 582–5.
- Donaldson DI, Petersen SE, Buckner RL. Dissociating memory retrieval processes using fMRI: evidence that priming does not support recognition memory. *Neuron* 2001; 31: 1047–59.
- Eustache F, Piolino P, Giffard B, Viader F, De La Sayette V, Baron JC, et al. 'In the course of time': a PET study of the cerebral substrates of autobiographical amnesia in Alzheimer's disease. *Brain* 2004; 127: 1549–60.
- Fleischman DA, Gabrieli JD. Repetition priming in normal aging and Alzheimer's disease: a review of findings and theories. *Psychol Aging* 1998; 13: 88–119.
- Folstein MF, Folstein SE, McHugh PR. 'Mini-mental state'. A practical method for grading the cognitive state of patients for the clinician. *J Psychiatr Res* 1975; 12: 189–98.
- Fox NC, Schott JM. Imaging cerebral atrophy: normal ageing to Alzheimer's disease. *Lancet* 2004; 363: 392–4.
- Gabrieli JD, Keane MM, Stanger BZ, Kjelgaard MM, Corkin S, Growdon JH. Dissociations among structural-perceptual, lexical-semantic and event-fact memory systems in Alzheimer, amnesic and normal subjects. *Cortex* 1994; 30: 75–103.
- Gabrieli JDE, Fleischman DA, Keane MM, Reminger SL, Morrell F. Double dissociation between memory systems underlying explicit and implicit memory in the human brain. *Psychol Sci* 1995; 6: 76–82.
- Gabrieli JDE, Brewer JB, Desmond JE, Glover GH. Separate neural bases of two fundamental memory processes in the human medial temporal lobe. *Science* 1997; 276: 264–6.
- Gabrieli JD, Vaidya CJ, Stone M, Francis WS, Thompson-Schill SL, Fleischman DA, et al. Convergent behavioural and neuropsychological evidence for a distinction between identification and production forms of repetition priming. *J Exp Psychol Gen* 1999; 128: 479–98.
- Glover GH, Lai S. Self-navigated spiral fMRI: interleaved versus single-shot. *Magn Reson Med* 1998; 39: 361–8.
- Golby A, Gabrieli J, Chiao J, Eberhardt J. Differential responses in the fusiform region to same- and other-race faces. *Nature Neurosci* 2001a; 4: 845–50.
- Golby A, Poldrack R, Brewer J, Spencer D, Desmond J, Gabrieli J. Material-specific lateralization in the medial temporal lobe and prefrontal cortex during memory encoding. *Brain* 2001b; 124: 1841–54.

- Golby A, Poldrack R, Illes J, Chen D, Desmond J, Gabrieli J. Memory lateralization in medial temporal lobe epilepsy assessed by functional MRI. *Epilepsia* 2002; 43: 855–63.
- Gron G, Bittner D, Schmitz B, Wunderlich A, Riepe M. Subjective memory complaints: Objective neural markers in patients with Alzheimer's disease and major depressive disorder. *Ann Neurol* 2002; 51: 491–8.
- Herholz K. PET studies in dementia. *Ann Nucl Med* 2003; 17: 79–89.
- Jagust WJ, Haan MN, Eberling JL, Wolfe N, Reed BR. Functional imaging predicts cognitive decline in Alzheimer's disease. *J Neuroimaging* 1996; 6: 156–60.
- Keane MM, Gabrieli JD, Fennema AC, Growdon JH, Corkin S. Evidence for a dissociation between perceptual and conceptual priming in Alzheimer's disease. *Behav Neurosci* 1991; 105: 326–42.
- Keane MM, Gabrieli JD, Mapstone HC, Johnson KA, Corkin S. Double dissociation of memory capacities after bilateral occipital-lobe or medial temporal-lobe lesions. *Brain* 1995; 118: 1129–48.
- Kirchhoff BA, Wagner Alzheimer's disease, Maril A, Stern CE. Prefrontal-temporal circuitry for episodic encoding and subsequent memory. *J Neurosci* 2000; 20: 6173–80.
- Lancaster J, Summerlin J, Rainey L, Freitas C, Fox P. The Talairach Daemon, a database server for Talairach Atlas Labels. *Neuroimage* 1997; 5: S633.
- Lewis DA, Campbell MJ, Terry RD, Morrison JH. Laminar and regional distributions of neurofibrillary tangles and neuritic plaques in Alzheimer's disease: a quantitative study of visual and auditory cortices. *J Neurosci* 1987; 7: 1799–808.
- Lustig C, Buckner RL. Preserved neural correlates of priming in old age and dementia. *Neuron* 2004; 42: 865–75.
- Martin A. Automatic activation of the medial temporal lobe during encoding: lateralized influences of meaning and novelty. *Hippocampus* 1999; 9: 62–70.
- Mesulam MM. From sensation to cognition. *Brain* 1998; 121: 1013–52.
- Rombouts SA, Barkhof F, Veltman DJ, Machielsen WC, Witter MP, Bierlaagh MA, et al. Functional MR imaging in Alzheimer's disease during memory encoding. *AJNR Am J Neuroradiol* 2000; 21: 1869–75.
- Saykin AJ, Flashman LA, Frutiger SA, Johnson SC, Mammourian AC, Moritz CH, et al. Neuroanatomic substrates of semantic memory impairment in Alzheimer's disease: patterns of functional MRI activation. *J Int Neuropsychol Soc* 1999; 5: 377–92.
- Schacter DL, Buckner RL. Priming and the brain. *Neuron* 1998; 20: 185–95.
- Schacter DL, Wagner AD. Medial temporal lobe activations in fMRI and PET studies of episodic encoding and retrieval. *Hippocampus* 1999; 9: 7–24.
- Scoville W, Milner B. Loss of recent memory after bilateral hippocampal lesions. *J Neurol Neurosurg Psychiatr* 1957; 20: 11–21.
- Simic G, Kostovic I, Winblad B, Bogdanovic N. Volume and number of neurons of the human hippocampal formation in normal aging and Alzheimer's disease. *J Comp Neurol* 1997; 379: 482–94.
- Small BJ, Herlitz A, Fratiglioni L, Almkvist O, Backman L. Cognitive predictors of incident Alzheimer's disease: a prospective longitudinal study. *Neuropsychology* 1997; 11: 413–20.
- Small SA, Perera GM, DeLaPaz R, Mayeux R, Stern Y. Differential regional dysfunction of the hippocampal formation among elderly with memory decline and Alzheimer's disease. *Ann Neurol* 1999; 45: 466–72.
- Small SA, Nava AS, Perera GM, Delapaz R, Stern Y. Evaluating the function of hippocampal subregions with high-resolution MRI in Alzheimer's disease and aging. *Microsc Res Tech* 2000; 51: 101–8.
- Sperling R, Greve D, Dale A, Killiany R, Holmes J, Rosas HD, et al. Functional MRI detection of pharmacologically induced memory impairment. *Proc Natl Acad Sci USA* 2002; 99: 455–60.
- Sperling R, Bates J, Chua E, Cocchiarella A, Rentz D, Rosen BR, et al. fMRI studies of associative encoding in young and elderly controls and mild Alzheimer's disease. *J Neurol Neurosurg Psychiatry* 2003; 74: 44–50.
- Squire LR. Memory and the hippocampus: a synthesis from findings with rats, monkeys and humans [published erratum appears in *Psychol Rev* 1992; 99: 582]. *Psychol Rev* 1992; 99: 195–231.
- Squire LR, Zola-Morgan S. The medial temporal lobe memory system. *Science* 1991; 253: 1380–6.
- Stern CE, Corkin S, Gonzalez RG, Guimaraes AR, Baker JR, Jennings PJ, et al. The hippocampal formation participates in novel picture encoding: evidence from functional magnetic resonance imaging. *Proc Natl Acad Sci USA* 1996; 93: 8660–5.
- Talairach J, Tournoux P. Co-planar atlas of the human brain. New York: Thieme; 1988.
- Tohgi H, Yonezawa H, Takahashi S, Sato N, Kato E, Kudo M, et al. Cerebral blood flow and oxygen metabolism in senile dementia of Alzheimer's type and vascular dementia with deep white matter changes. *Neuroradiology* 1998; 40: 131–7.
- Tulving E, Markowitsch HJ, Craik FE, Habib R, Houle S. Novelty and familiarity activations in PET studies of memory encoding and retrieval. *Cereb Cortex* 1996; 6: 71–9.
- Yamaguchi S, Meguro K, Itoh M, Hayasaka C, Shimada M, Yamazaki H, et al. Decreased cortical glucose metabolism correlates with hippocampal atrophy in Alzheimer's disease as shown by MRI and PET. *J Neurol Neurosurg Psychiatry* 1997; 62: 596–600.